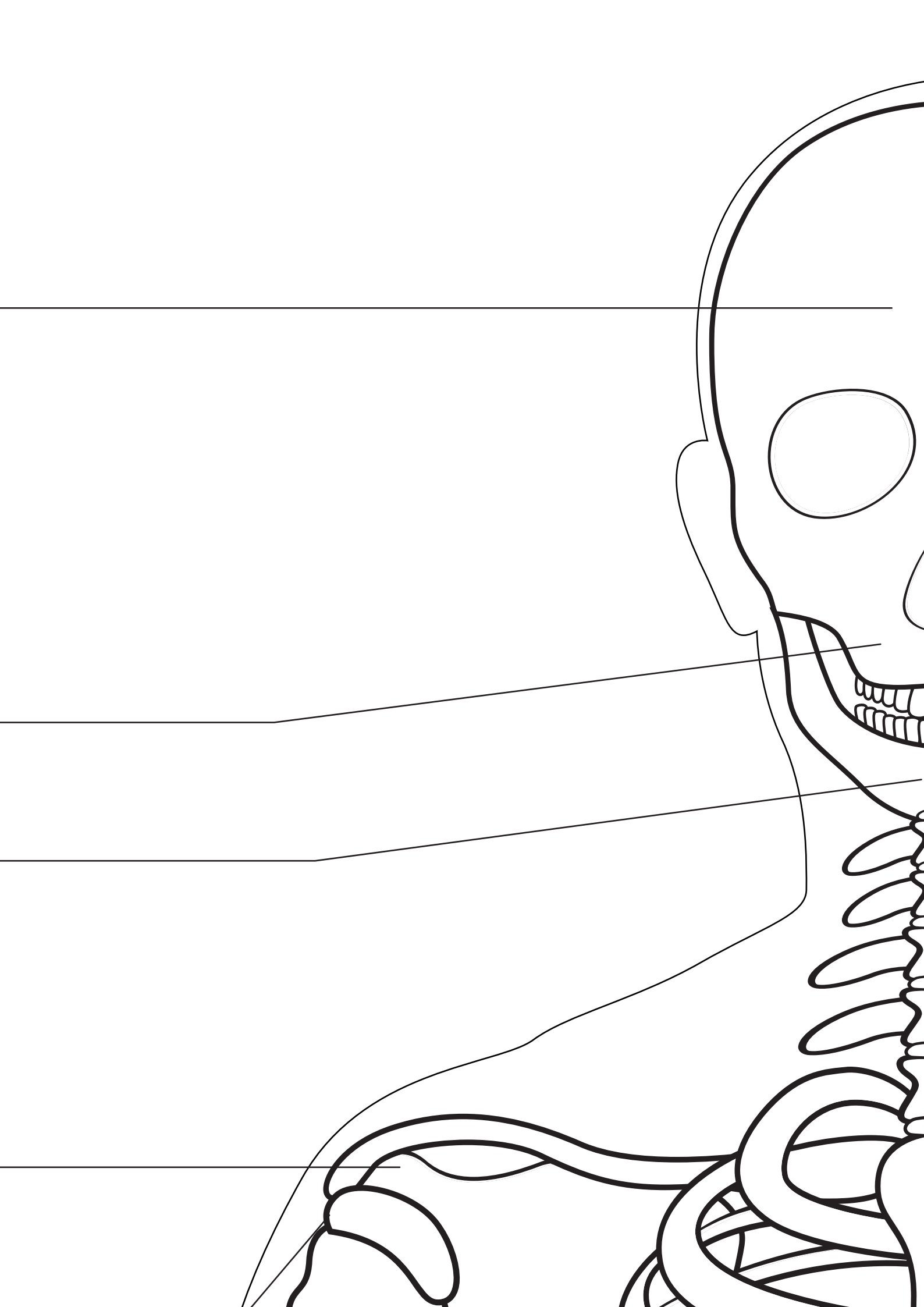


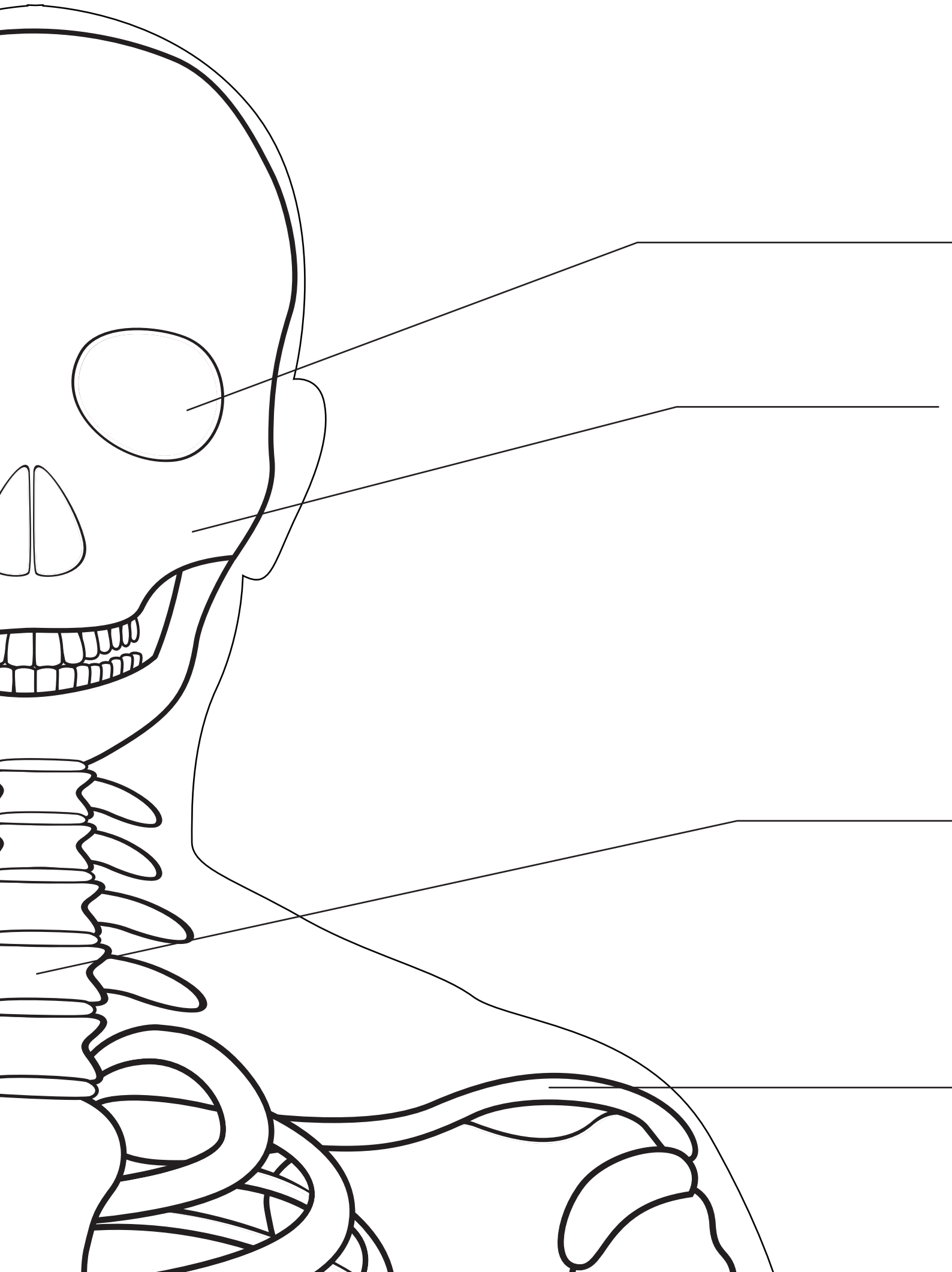
Frontal Bone _____

Maxilla _____

Mandible _____

Acromion _____





Orbit

Zygomatic Bone

Cervical Spine

Clavicle

Coracoid Process

Scapula



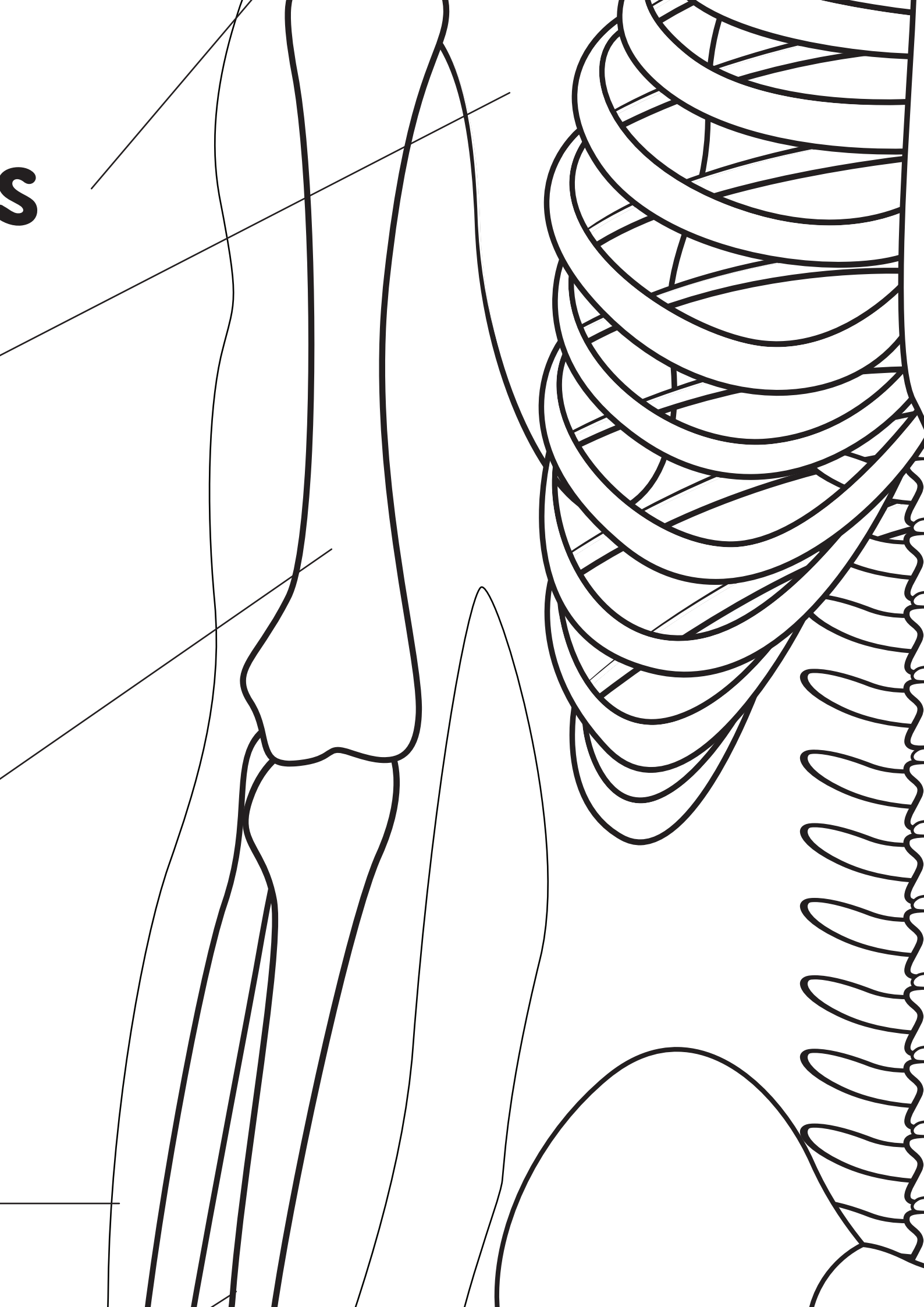
Humerus

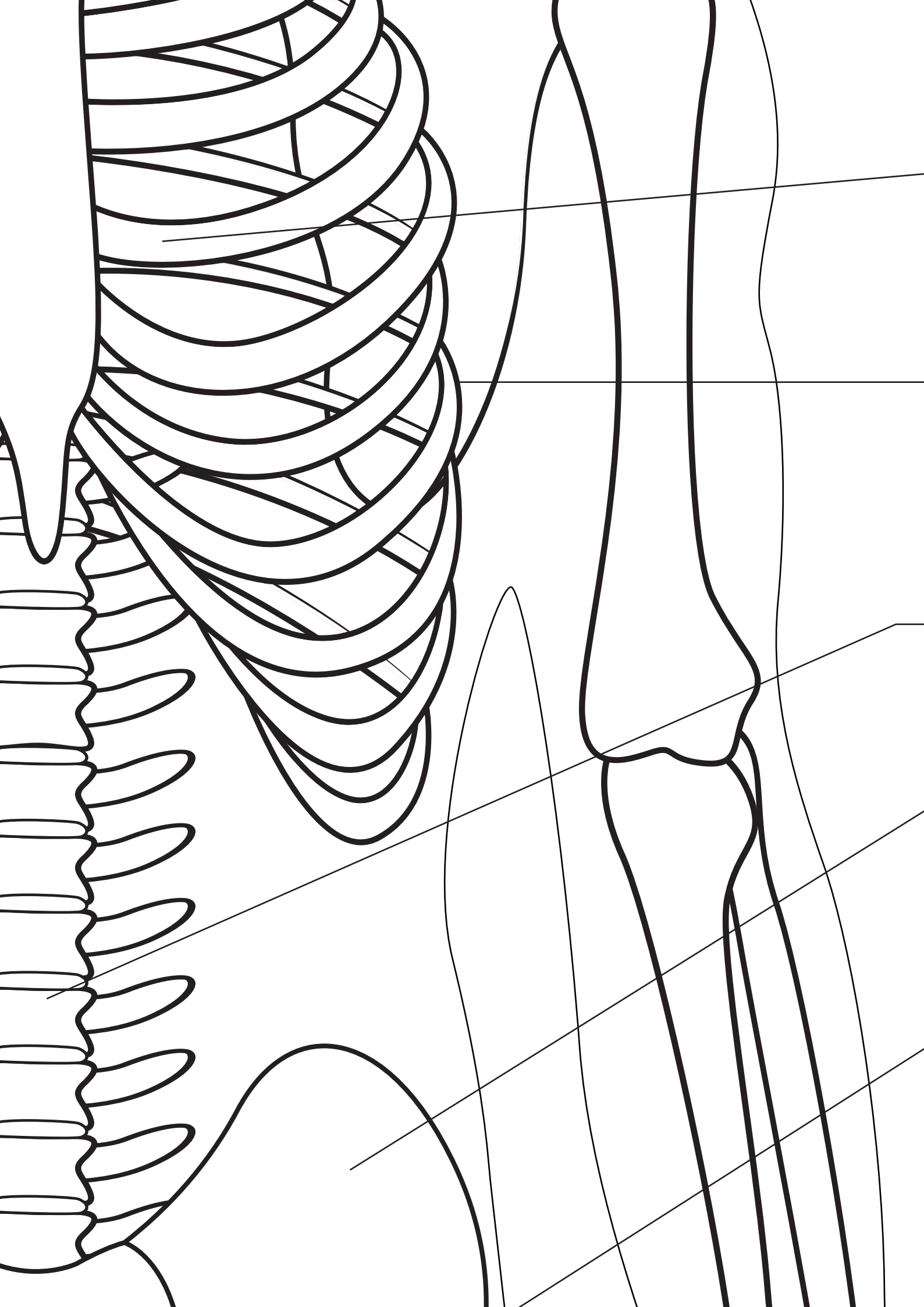


Radius



S







Sternum



Ribs



Lumbar Spine



Ilium



Pubis

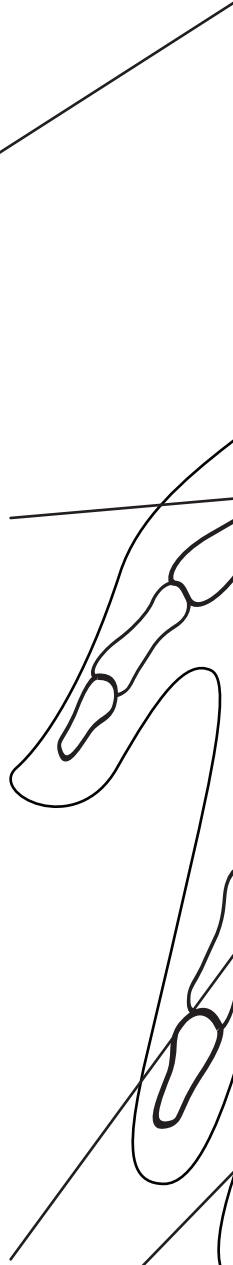Ulna

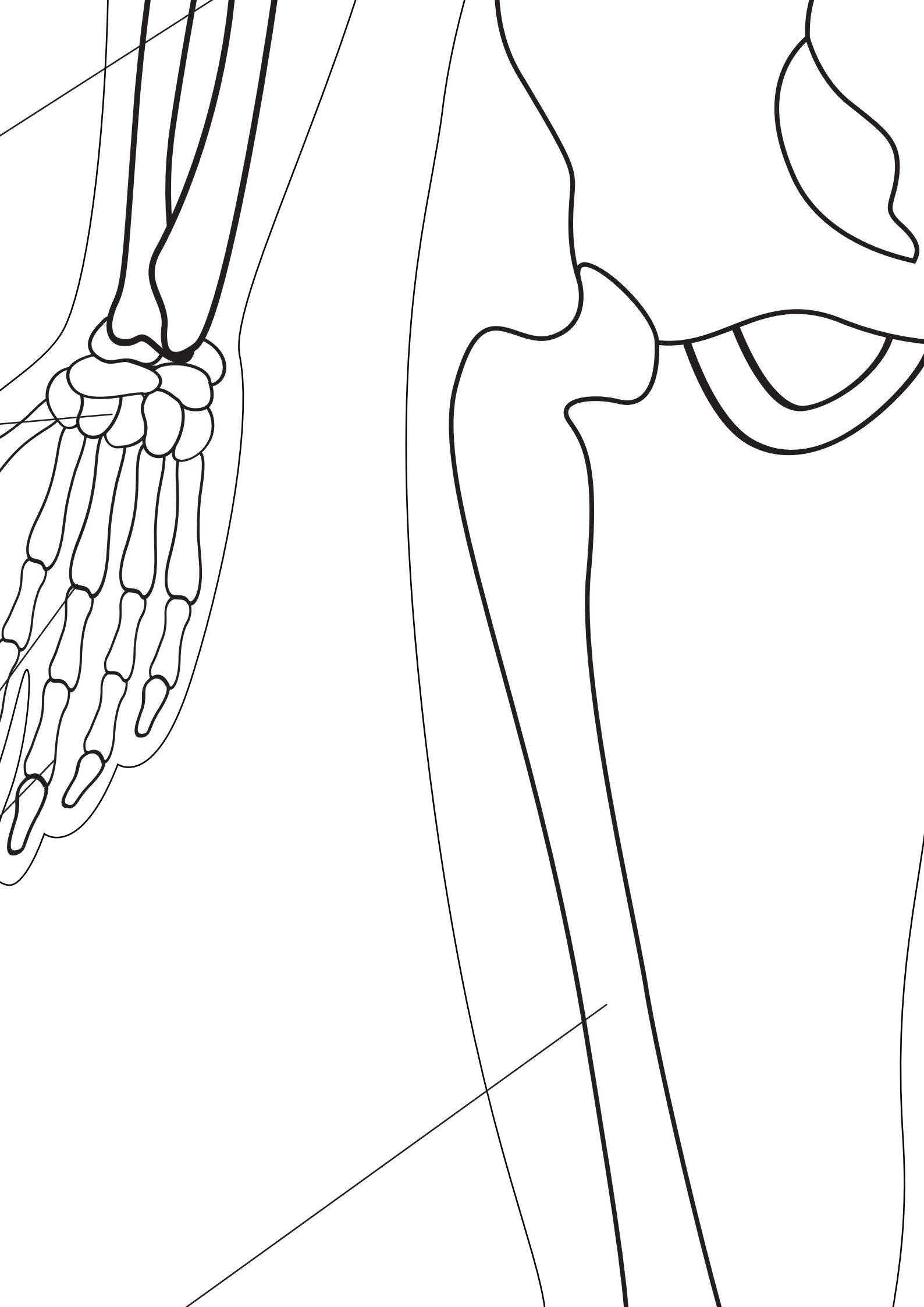
Carpal Bones

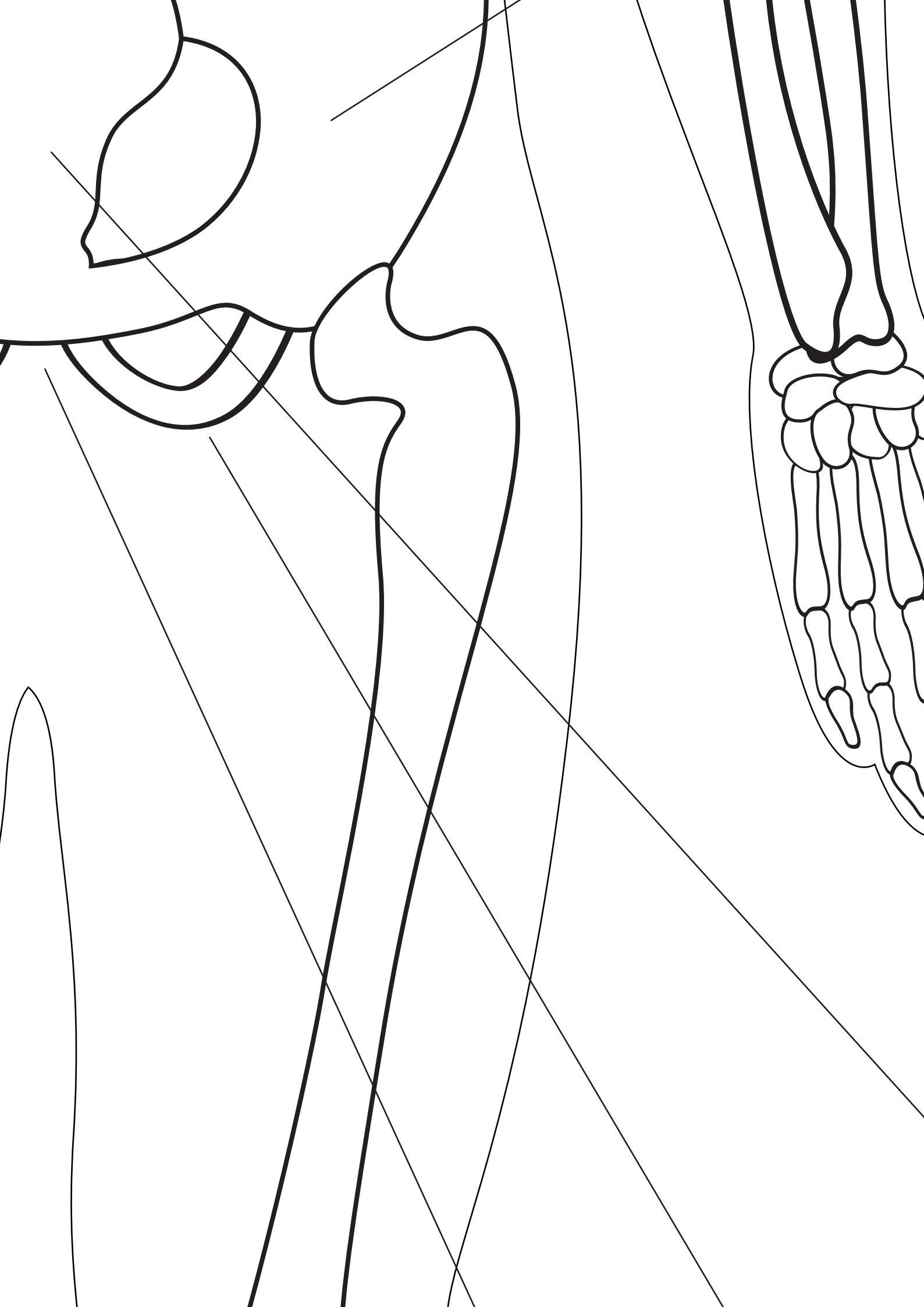
Metacarpals

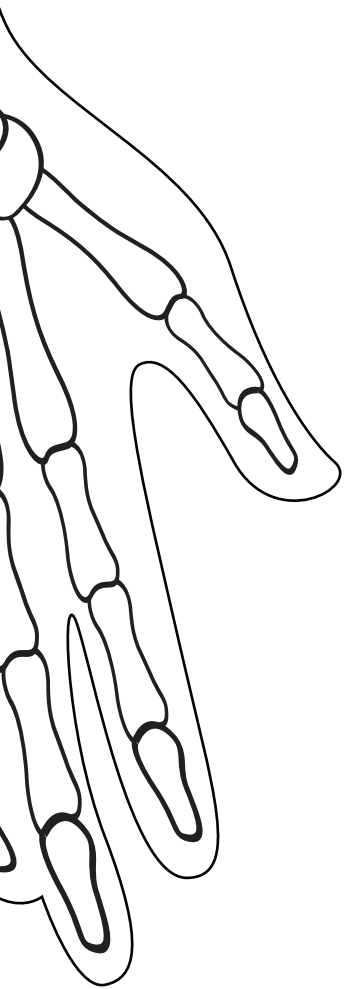
Phalanges

Femur









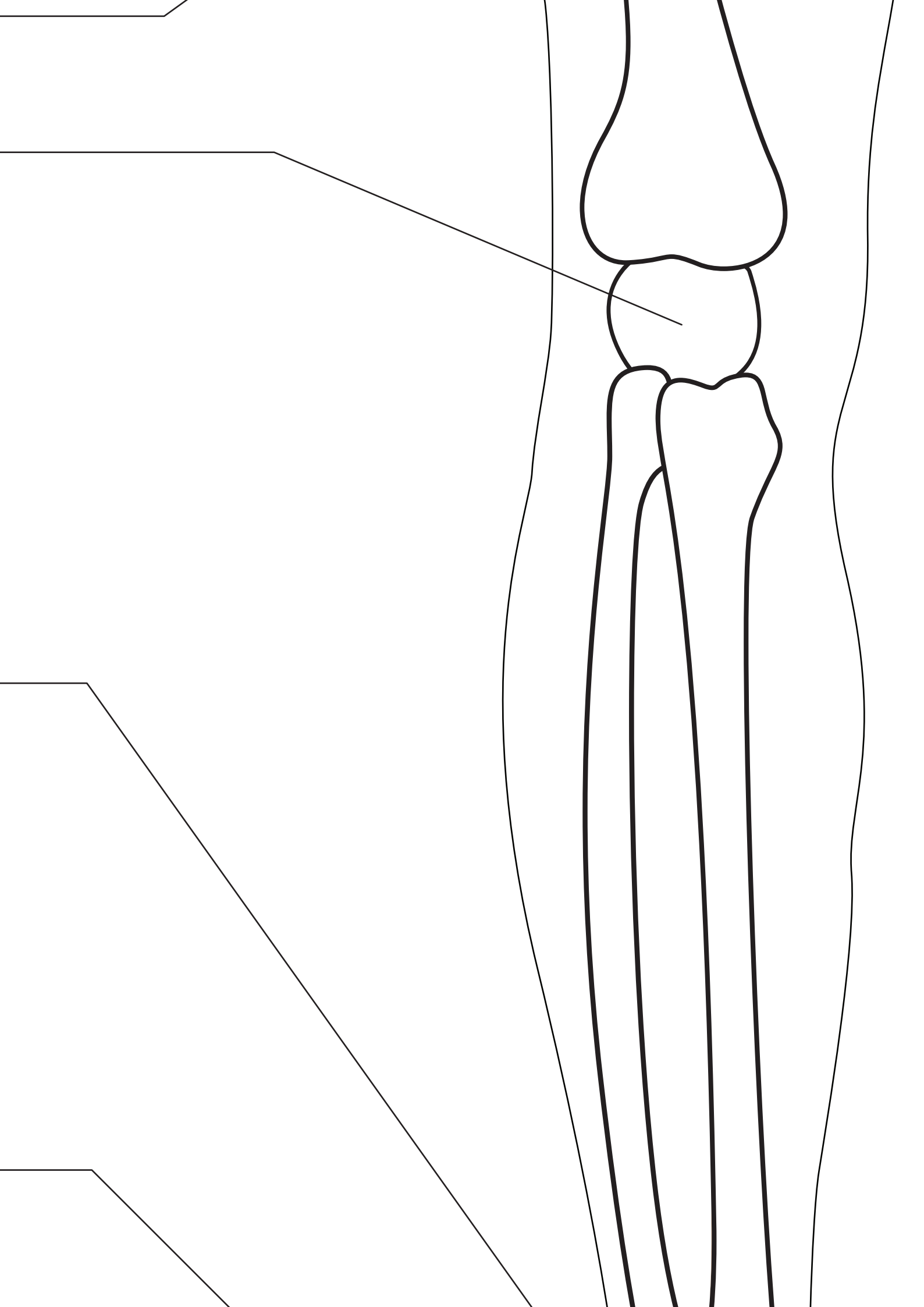
Sacrum

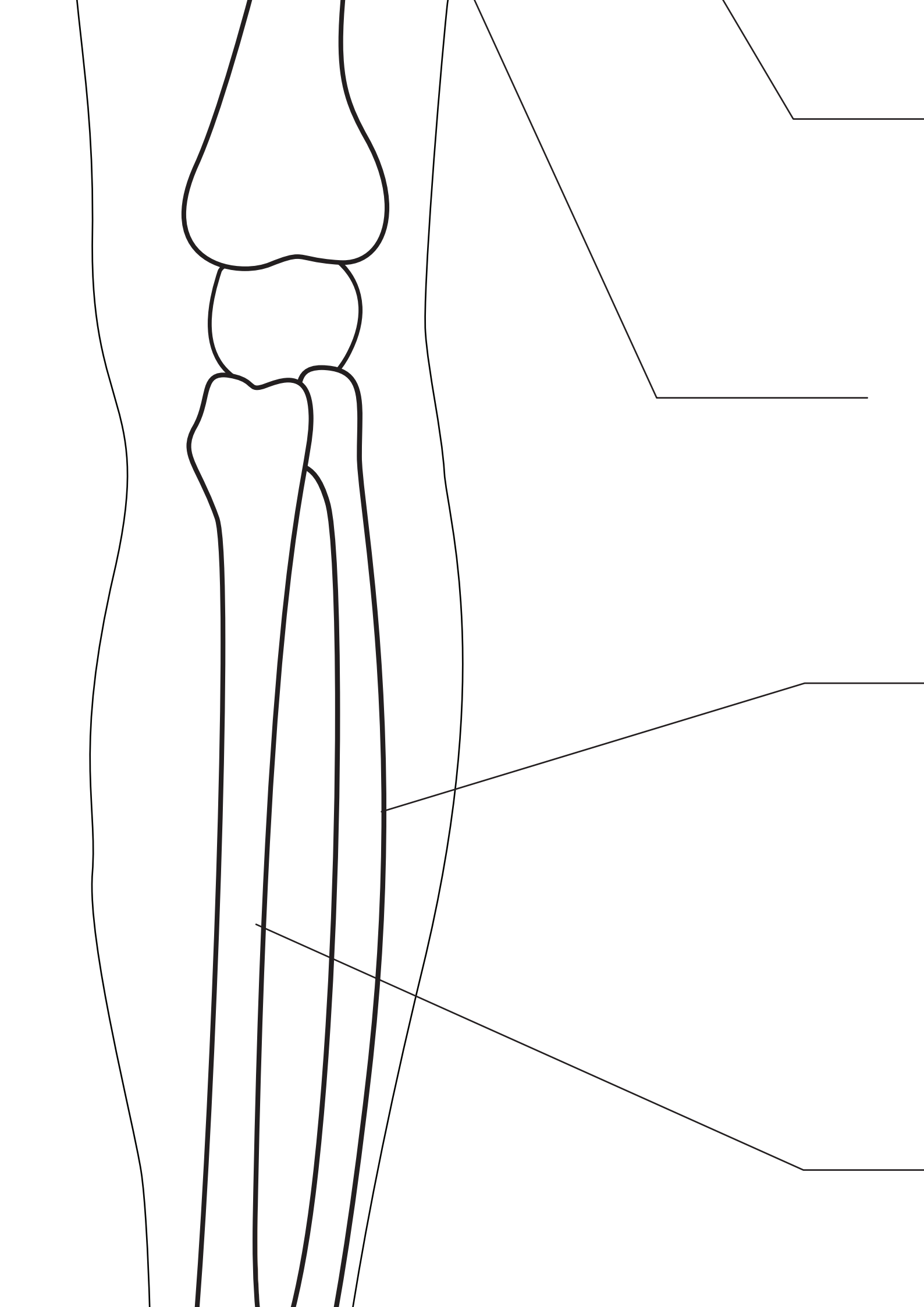
femur _____

Patella _____

Tarsai Bones _____

Metatarsal _____





Ischium

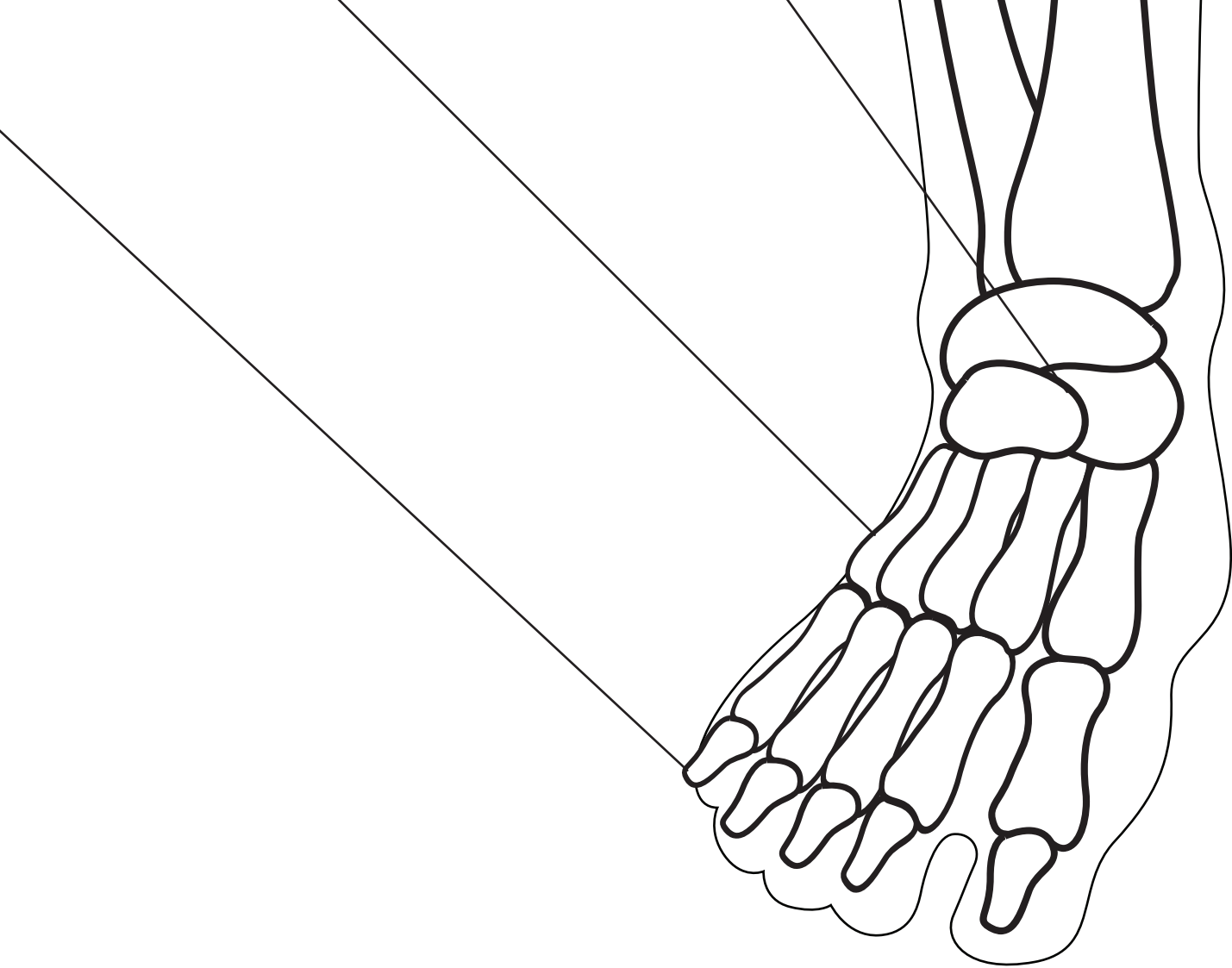
Pubic Symphysis

Fibula

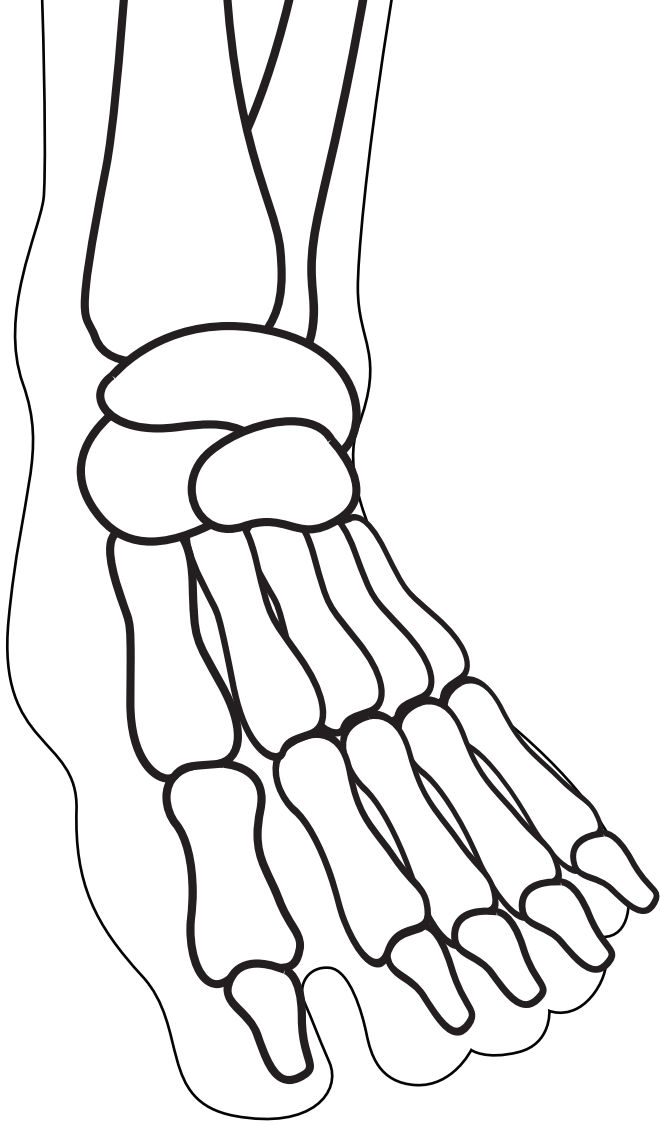
Tibia

Phalanges

THE S



SKELETON



AL SY

STEM